ROSACEA - IMMUNOMODULATION BY ANTIBIOTICS, LASER THERAPY AND NANOTECHNOLOGY

VICTOR GABRIEL CLATICI, BUCHAREST, ROMANIA

HEALTH AND BEAUTY

SKIN = The first aspect evaluated when we meet someone…


Vineri
Friday
Vendredi
14
Septembrie
September
Septembre
08
09
10
11
12
13
14
15

- 1.History,
- 2.Epidemiology,
- 3. Quality of Life,
- 4. Associated diseases,
- 5. Pathogeny,
- 6. Holistic approach of rosacea,
- 7. Treatment – immunomodulatory aspects,
- 8. Conclusions.

HISTORY OF ROSACEA

- images in Louvre from 15th century.

Cribier B. Medical history of the representation of rosacea in the 19th century. J Am Acad Dermatol. 2013;69(6 Suppl 1):S2–S14.

- psychiatric illness and alcoholism = ,,causes,, of rosacea,
- facial erythema = social stigma.

Plesch E. A Rorschach study of rosacea and morbid blushing. Br J Med Psychol 1951;24:202-5.

Whitlock FA. Psychosomatic aspects of rosacea. Br J Dermatol 1961;73:137-48.

Cribier B. The red face: art, history and medical representations. Ann Dermatol Venereol 2011;138(Suppl):S172-8.

Definition / signs / symptoms

- chronic inflammatory skin disease,
- erythema, papules, telangiectasia, edema, pustules, or a combination (1)
- central face - cheeks, forehead, chin, and nose (2).
- facial flushing, stinging , pain, burning sensations.

- 1. Steinhoff, M.; Schauber, J.; Leyden, J.J. New insights into rosacea pathophysiology: A review of recent findings. *J. Am. Acad. Dermatol.* **2013**, *69*, S15–S26.
- 2. Tan, J.; Berg, M. Rosacea: Current state of epidemiology. *J. Am. Acad. Dermatol.* **2013**, *69*, S27–S35.

Epidemiology - Rosacea

- Prevalence = **1.5% to 10%** - northern European countries (1,2,5)
- Prevalence = **5%** - USA (3,4,5)

- 1. Berg M et al, 1989. 2. Lomholt G, 1964. 3. Bamford JTM, 2001. 4. Zuber TJ, 2000.

  5. BE Elewski et al 2011.

Classification

- erythematotelangiectatic (1), papulopustular (2), phymatous (3), and ocular (4),
- the severity = 1 (mild), 2 (moderate), or 3 (severe).

Wilkin J, Dahl M, Detmar M, et al. Standard classification of rosacea: report of the National Rosacea Society Expert Committee on the Classification and Staging of Rosacea. J Am Acad Dermatol 2002;46:584-7.

Wilkin J, Dahl M, Detmar M, et al. Standard grading system for rosacea: report of the National Rosacea Society Expert Committee on the Classification and Staging of Rosa- cea. J Am Acad Dermatol 2004;50:907-12.

Quality of life can be defined either by the absence of disease or through productive and enjoyable life.

1984 Calman :,, Quality of life is present when hopes are appropriate with individual experience,,

- skin disorders have a negative impact on the psychological and emotional health,,
- depression,
- a decreased sense of body image and self-esteem,
- sexual and relationship difficulties,
- a general reduction in quality of life.

Dungey RK, Busselmeir TJ. Medical and psychosocial aspects of psoriasis. Health Soc Work. 1982;7:140–7.

Obermeyer A. Psychoses and disorders of the skin: psychocutaneous medicine. Illinois: Thomas Publishing; 1985.

Porter JR, Beuf AH, Lerner A, Nordlund J. Response to cosmetic disfigurement: patients with vitiligo. Cutis. 1987;39:493–4.

Papadopoulos L, Bor R. Psychological approaches to dermatology. Leicester: BPS; 1999.

Walker C, Papadopoulos L. Psychodermatology. Cambridge: Cambridge University Press; 2005.

Experience of patients with rosacea (1-4)

- embarrassment (70%),
- low self-esteem (75%),
- frustration,
- impaired social functioning,
- social and professional isolation.

- 1. Clatici VG. TOMORROW HEALTH AND BEAUTY STARTING TO DAY – A DAILY LIFE FOR CHARISMA AND SUCCESS! ROSACEA – A BIG NEGATIVE IMPACT ON CHARISMA AND FIRST IMPRESSION! WHAT WE CAN DO? Anti Aging Medicine World Congress – Monte Carlo, Monaco, 26-28 March, 2015
- 2. National Rosacea Society. Coping with Rosacea. Tips on Lifestyle Management for Rosacea Sufferers. National Rosacea Society, Barrington, IL, 1996.
- 3. Zuber TJ. Rosacea. Prim Care 2000; 27: 309–318.
- 4. Shear N, Levine C. Needs survey of Canadian rosacea patients. J Cutan Med Surg 1999; 3: 178–181.


DIABETES


CANCER
TISSUE
DIAGNOSI
HOPE
GENERAL
LEUKEMIA
PROGNOSIS
TREATED
REPLICATION
CARCINOGENS
GENETIC
TYPE
ABNORMALITIES
MALIGNANT
USUALLY
FIGHT
DIVISION
MEDICAL
SCIENCE
TUMORS
GROUP
LOCATION
TISSUES
SEVERE
GENES
CANCERS
NORM
RESEAR
STAGE
DERIVE
CHEMOTHERAP
NEW
RADIOTHERAPY
BODY
MOLECULAR
TREATMENTS
COMPLICATIONS
PROPERTIES
LOSS
CELL
MUTATION
CELLS
HISTOLOGIC
GROWTH
RESEMBLES
TYPICALLY
TUMOR
DNA
COMMON
OFTEN
FOUND
WELL
SPECIFIC


tremor at rest
elderly
progresses
dementia
emotional problems
central nervous system
shaking
formation
disease
death
behavioural problems
symptoms
factors
syndrome
sensory
neurons
parkinsonism
parkinson's disease
slowing of movement
parkinson's
dopamine
drugs
pathology
risk
motor symptoms
protein
brain
degenerative disorder
stiffness

ROSACEA - CARDIOVASCULAR DISEASES

- High total cholesterol (>200 mg/dL), LDL (>130 mg/dL) and CRP (>0.8 mg/L) levels,
- a family history of premature CVD,
- a history of smoking and alcohol consumption,
- **CVD - significantly more common in the rosacea patients compared to controls.**
- N. Duman et al 2014.

- a higher risk of cardiovascular comorbidities - hypertension, dyslipidemia, coronary artery disease (1-3)
- rosacea severity related to cardiovascular comorbidities (3).

- 1. Hua, T.C.; Chung, P.I.; Chen, Y.J.; Wu, L.C.; Chen, Y.D.; Hwang, C.Y.; Chu, S.Y.; Chen, C.C.; Lee, D.D.; Chang, Y.T.; et al. Cardiovascular comorbidities in patients with rosacea: A nationwide case-control study from Taiwan. *J. Am. Acad. Dermatol.* **2015**, *73*, 249–254
- 2. Duman, N.; Ersoy Evans, S.; Atakan, N. Rosacea and cardiovascular risk factors: A case control study. *J. Eur. Acad. Dermatol. Venereol.* **2014**, *28*, 1165–1169.
- 3. Rainer, B.M.; Fischer, A.H.; Luz Felipe da Silva, D.; Kang, S.; Chien, A.L. Rosacea is associated with chronic systemic diseases in a skin severity-dependent manner: Results of a case-control study. *J. Am. Acad. Dermatol.* **2015**, *73*, 604–608.

ROSACEA AND DIGESTIVE DISORDERS

- inflammatory bowel diseases,
- ulcerative colitis,
- Crohn’s disease,
- celiac disease,
- SIBO,

- 1. Chang, A.L.; Raber, I.; Xu, J.; Li, R.; Spitale, R.; Chen, J.; Kiefer, A.K.; Tian, C.; Eriksson, N.K.; Hinds,D.A.;etal. Assessment of the genetic basis of rosacea by genome-wide association study. *J. Investig. Dermatol.* **2015**, *135*, 1548–1555.
- 2. Silverberg, M.S.; Cho, J.H.; Rioux, J.D.; McGovern, D.P.; Wu, J.; Annese, V.; Achkar, J.P.; Goyette, P.; Scott, R.; Xu, W.; et al. Ulcerative colitis-risk loci on chromosomes 1p36 and 12q15 found by genome-wide association study. *Nat. Genet.* **2009**, *41*, 216–220.
- 3. Weinstock, L.B.; Steinhoff, M. Rosacea and small intestinal bacterial overgrowth: Prevalence and response to rifaximin. *J. Am. Acad. Dermatol.* **2013**, *68*, 875–876.
- 4. Spoendlin, J.; Karatas, G.; Furlano, R.I.; Jick, S.S.; Meier, C.R. Rosacea in patients with ulcerative colitis and crohn's disease: a population-based case-control study. *Inflamm. Bowel Dis.* **2016**, *22*, 680–687.
- 5. Egeberg, A.; Hansen, P.R.; Gislason, G.H.; Thyssen, J.P. Clustering of autoimmune diseases in patients with rosacea. *J. Am. Acad. Dermatol.* **2016**, *74*, 667–672.e1.

Comorbidities – autoimmune diseases

- Clustering of autoimmune diseases in patients with rosacea
- A Egeberg, PR Hansen, GH Gislason, JP Thyssen, J Am Acad Derm, DOI: http://dx.doi.org/10.1016/j.jaad.2015.11.004
- **women** = rosacea is associated with T1DM, celiac disease, multiple sclerosis, rheumatoid arthritis.
- **men** – rosacea is associated with rheumatoid arthritis.

PATHOGENESIS…UNCLEAR…

- **Neurovascular** changes, stimulation by various **microbes**, abnormal function of **innate immunity** in the skin,

Yamasaki K, Gallo RL. The molecular pathology of rosacea. J Dermatol Sci 2009;55:77-81.

- **Vascular** abnormalities, dermal matrix degeneration, **environmental** factors, **microorganisms**,

Elewski BE, Draelos Z, Dreno B, et al. Rosacea-global diversity and optimized outcome: proposed international consensus from the Rosacea International Expert Group. *J Eur Acad Dermatol Venereol*. 2011;25:188–200.

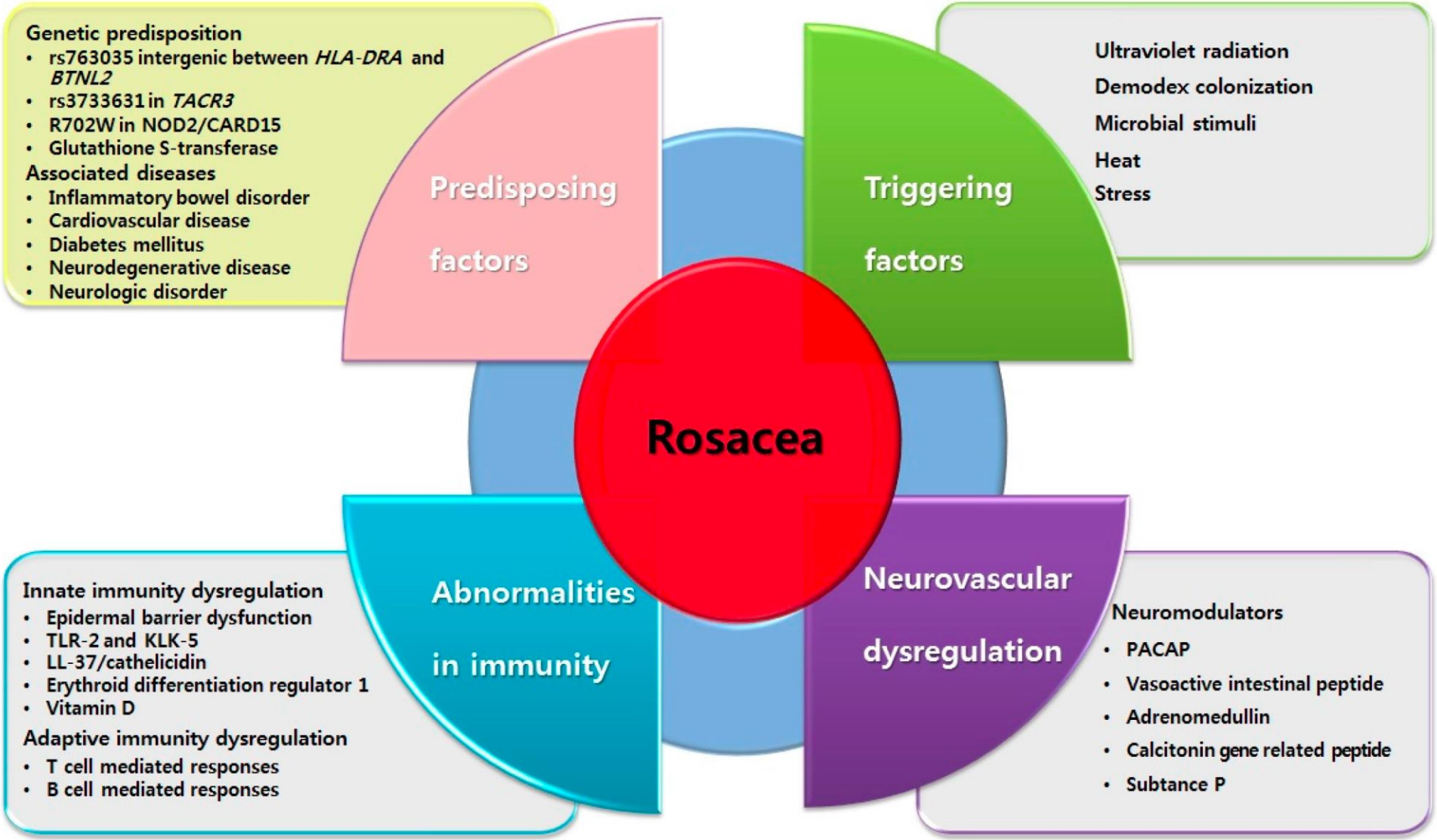

Rosacea: Molecular Mechanisms and Management of a Chronic Cutaneous Inflammatory Condition

Yu Ri Woo, Ji Hong Lim,Dae Ho Cho, Hyun Jeong Park,

Int. J. Mol. Sci. 2016, *17*, 1562; doi:10.3390/ijms17091562

IMMUNE MODIFICATIONS – INNATE…

- disruption of epidermal barrier (direct effect of Demodex folliculorum),
- increased expression of TLR2 (consecutive production of IL-8, IL-1β, TNF-α),
- activation of KLK5 (Kallikrein-5) - lithic effects and production of cathelicidin LL – 37 (with effects on immune modulation and inflammation),
- serum levels of vitamin D = higher.

TLR-2 and KLK-5

- the expression of TLR-2 is increased (acne, rosacea),

Yamasaki, K.; Kanada, K.; Macleod, D.T.; Borkowski, A.W.; Morizane, S.; Nakatsuji, T.; Cogen, A.L.; Gallo, R.L. TLR2 expression is increased in rosacea and stimulates enhanced serine protease production by keratinocytes. J. Investig. Dermatol. 2011, 131, 688–697.

Ozlu, E.; Karadag, A.S.; Ozkanli, S.; Oguztuzun, S.; Kilic, M.; Zemheri, E.; Akbulak, O.; Akdeniz, N. Comparison of TLR-2, TLR-4, and antimicrobial peptide levels in different lesions of acne vulgaris. Cutan. Ocul. Toxicol. 2015.

- TLR-2 (activated by external stimuli or triggering factors) - effects on keratinocytes (proinflammatory cytokines and chemokines).

- skin samples from patients with rosacea exhibit increased gene expression for proinflammatory cytokines (IL-8, IL-1β, and TNF-α) .

Casas, C.; Paul, C.; Lahfa, M.; Livideanu, B.; Lejeune, O.; Alvarez-Georges, S.; Saint-Martory, C.; Degouy, A.; Mengeaud, V.; Ginisty, H.; et al. Quantification of Demodex folliculorum by PCR in rosacea and its relationship to skin innate immune activation. Exp. Dermatol. 2012, 21, 906–910.

- IL-8 = chemotaxis of neutrophils in the skin / the release of proteases including cathepsin G, elastase, and protease-3 .

Meyer-Hoffert, U.; Schröder, J.M. Epidermal proteases in the pathogenesis of rosacea. J. Investig. Dermatol. Symp. Proc. 2011, 15, 16–23.

- IL-1β and TNF-α have an additional role as angiogenic factors VEGF.

Gerber, P.A.; Buhren, B.A.; Steinhoff, M.; Homey, B. Rosacea: The cytokine and chemokine network. J. Investig. Dermatol. Symp. Proc. 2011, 15, 40–47.

- Demodex / Ultraviolet radiation = activated the the expression of TLR-2.
- TLR-2 regulates the release of KLK-5 (disrupts the epidermal barrier/ activates the cleavage of hCAP-18 into LL-37

Yamasaki, K.; Schauber, J.; Coda, A.; Lin, H.; Dorschner, R.A.; Schechter, N.M.; Bonnart, C.; Descargues, P.; Hovnanian, A.; Gallo, R.L. Kallikrein-mediated proteolysis regulates the antimicrobial effects of cathelicidins in skin. FASEB J. 2006, 20, 2068–2080.

- the lesional skin of patients with rosacea express more KLK-5 than the skin of healthy controls.

Yamasaki, K.; di Nardo, A.; Bardan, A.; Murakami, M.; Ohtake, T.; Coda, A.; Dorschner, R.A.; Bonnart, C.; Descargues, P.; Hovnanian, A.; et al. Increased serine protease activity and cathelicidin promotes skin inflammation in rosacea. Nat. Med. 2007, 13, 975–980.

LL-37/Cathelicidin

- increased expression of cathelicidin in the epidermis,

Marcinkiewicz, M.; Majewski, S. The role of antimicrobial peptides in chronic inflammatory skin diseases. Postep. Dermatol. Alergol. 2016, 33, 6–12.

- only a single cathelicidin gene, cathelicidin AMP (CAMP),

Cowland, J.B.; Johnsen, A.H.; Borregaard, N. hCAP-18, a cathelin/pro-bactenecin-like protein of human neutrophil specific granules. FEBS Lett. 1995, 368, 173–176.

- the propeptide of CAMP = LL-37,

Gudmundsson, G.H.; Agerberth, B.; Odeberg, J.; Bergman, T.; Olsson, B.; Salcedo, R. The human gene FALL39 and processing of the cathelin precursor to the antibacterial peptide LL-37 in granulocytes. Eur. J. Biochem. 1996, 238, 325–332.

LL-37 AND ROSACEA

- higher levels of LL-37 than controls,

Yamasaki, K.; di Nardo, A.; Bardan, A.; Murakami, M.; Ohtake, T.; Coda, A.; Dorschner, R.A.; Bonnart, C.; Descargues, P.; Hovnanian, A.; et al. Increased serine protease activity and cathelicidin promotes skin inflammation in rosacea. Nat. Med. 2007, 13, 975–980.

Salzer, S.; Ruzicka, T.; Schauber, J. Face-to-face with anti-inflammatory therapy for rosacea. Exp. Dermatol. 2014, 23, 379–381.

- the higher molecular weight forms of LL-37,

Yamasaki, K.; di Nardo, A.; Bardan, A.; Murakami, M.; Ohtake, T.; Coda, A.; Dorschner, R.A.; Bonnart, C.; Descargues, P.; Hovnanian, A.; et al. Increased serine protease activity and cathelicidin promotes skin inflammation in rosacea. Nat. Med. 2007, 13, 975–980.

Koczulla, R.; von Degenfeld, G.; Kupatt, C.; Krotz, F.; Zahler, S.; Gloe, T.; Issbrucker, K.; Unterberger, P.; Zaiou, M.; Lebherz, C.; et al. An angiogenic role for the human peptide antibiotic LL-37/hCAP-18. J. Clin. Investig. 2003, 111, 1665–1672.

LL-37 FUNCTIONS

- antimicrobial activity,
- immune modulation, neutrophil chemotaxis, induction of cytokine and chemokine release from mast cells.

Yamasaki, K.; Gallo, R.L. Rosacea as a disease of cathelicidins and skin innate immunity. J. Investig. Dermatol. Symp. Proc. 2011, 15, 12–15.

Zheng, Y.; Niyonsaba, F.; Ushio, H.; Nagaoka, I.; Ikeda, S.; Okumura, K.; Ogawa, H. Cathelicidin LL-37 induces the generation of reactive oxygen species and release of human α-defensins from neutrophils. Br. J. Dermatol. 2007, 157, 1124–1131.

- stimulates tissue inflammation, vasodilation, and angiogenesis in rosacea,
- facilitates the degranulation of mast cells (enhances the expression of MMP-1, MMP-9, and IL-6).

Vitamin D

- serum vitamin D levels were found to be higher than those of the control groups .
- the pathogenesis of rosacea appears to differ somewhat from that of other chronic cutaneous inflammatory diseases.
- Ekiz, O.; Balta, I.; Sen, B.B.; Dikilitaş, M.C.; Ozuğuz, P.; Rifaioğlu, E.N. Vitamin D status in patients with rosacea. Cutan. Ocul. Toxicol. 2014, 33, 60–62.

Dysregulation in Adaptive Immunity

- **T Cell-Mediated Responses**

1. increase of CD4+ over CD8+ T cells among the T cell population,
2. upregulation of Th1 and Th17.

Buhl, T.; Sulk, M.; Nowak, P.; Buddenkotte, J.; McDonald, I.; Aubert, J.; Carlavan, I.; Deret, S.; Reiniche, P.; Rivier, M.; et al. Molecular and morphological characterization of inflammatory infiltrate in rosacea reveals activation of Th1/Th17 pathways. J. Investig. Dermatol. 2015, 135, 2198–2208.

- **B Cell-Mediated Responses**

Buhl, T.; Sulk, M.; Nowak, P.; Buddenkotte, J.; McDonald, I.; Aubert, J.; Carlavan, I.; Deret, S.; Reiniche, P.; Rivier, M.; et al. Molecular and morphological characterization of inflammatory infiltrate in rosacea reveals activation of Th1/Th17 pathways. J. Investig. Dermatol. 2015, 135, 2198–2208.

Cribier, B. Rosacea under the microscope: Characteristic histological findings. J. Eur. Acad. Dermatol. Venereol. 2013, 27, 1336–1343.

Woźniacka, A.; Salamon, M.; McCauliffe, D.; Sysa-Jędrzejowska, A. Antinuclear antibodies in rosacea patients. Postep. Dermatol. Alergol. 2013, 30, 1–5.

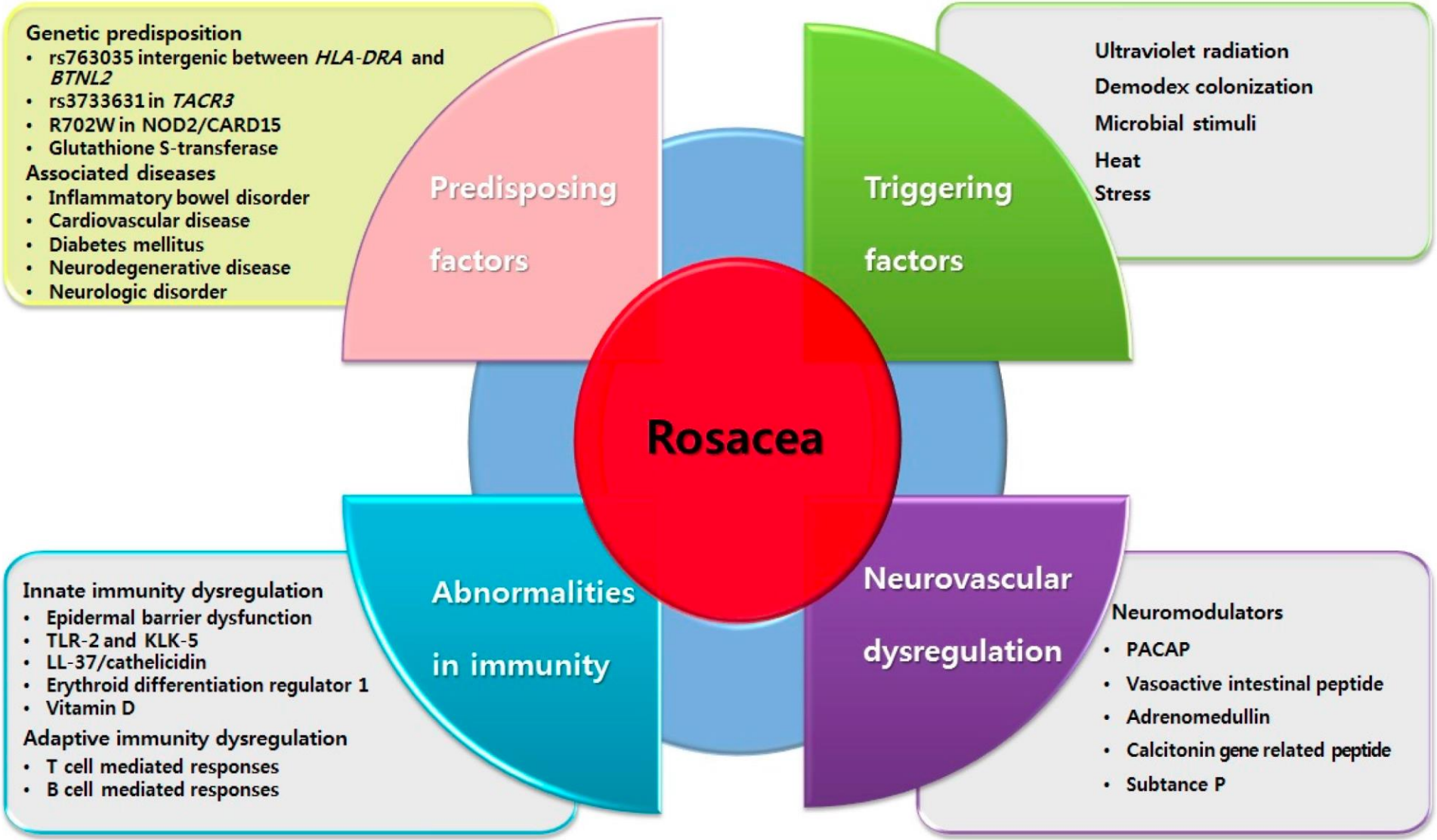

Rosacea: Molecular Mechanisms and Management of a Chronic Cutaneous Inflammatory Condition

Yu Ri Woo, Ji Hong Lim,Dae Ho Cho, Hyun Jeong Park,

Int. J. Mol. Sci. 2016, *17*, 1562; doi:10.3390/ijms17091562


Changes
NEXT EXIT


CHANGE
AHEAD

The 3 steps in Rosacea – systematic approach

- ,,the team for rosacea,,
- **Nobody is perfect, so we need a team!**
- If YOU are NOT a dermatologist, please refer to a colleague in order to have an holistic approach!

YOU – Step 1

- Consultation (history / type and severity of rosacea / trigger / associated conditions / contraindication for laser),
- Assess patient concerns and expectations,
- Principles of skin care (gentle cleansing, moisturizing, photoprotection),
- Principles of diet,
- ,,Plan of action,,.

- Del Rosso JQ. Advances in understanding and managing rosacea. Part 2: the central role, evaluation, and medical management of diffuse and persistent facial erythema of rosacea. J Clin Aesthet Dermatol. 2012;5(3):26–36.

TEAM – step 2

- Investigation for associated conditions / associated diseases.

ROSACEA AND IMAGISTIC

- bioengineering techniques (scanning laser doppler, video microscopy, skin surface temperature, pH, colorimetry, digital photography)
- **noninvasive** tool,
- first **evaluation** of the patient,
- **monitoring** the treatment.

YOU – step 3

- Diet = alimentary journal,
- Skin care = principles / photoprotection / make up,
- Local and general treatment,
- EBD treatments = IPL, NIR, vascular laser.

- educate and monitor for possible triggers,
- individual risk factor profile - ,,journal of patient,, - 4 weeks.
- AK Gupta et al 2005.

The goals of treatment

- Healing and prevention of active lesions,
- Prevention of scar,
- Improving the quality of life of patients,
- Decreasing the negative psychological impact.

EVIDENCE…

- High quality evidence = topical azelaic acid, topical ivermectin, brimonidine, doxycycline and isotretinoin.
- Moderate quality evidence = metronidazole and oral tetracycline.
- Low quality evidence = low dose minocycline, laser and intense pulsed light therapy.

- van Zuuren EJ, Fedorowicz Z Carter B, van der Linden MM, Charland L. **Interventions for rosacea.** Cochrane Database Syst Rev. 2015 Apr 28;4:CD003262. doi: 10.1002/14651858.CD003262.pub5.

GENERAL DERMATOLOGY

BJD
British Journal of Dermatology

Rosacea treatment update: recommendations from the global ROSacea COnsensus (ROSCO) panel

M. Schaller,[1] L.M.C. Almeida,[2] A. Bewley,[3,4] B. Cribier,[5] N.C. Dlova,[6] G. Kautz,[7] M. Mannis,[8] H.H. Oon,[9] M. Rajagopalan,[10] M. Steinhoff,[11] D. Thiboutot,[12] P. Troielli,[13] G. Webster,[14] Y. Wu,[15] E. van Zuuren[16] and J. Tan[17]

[1]Department of Dermatology, Universitatsklinikum Tubingen, Tubingen, Baden-Württemberg, Germany
[2]Faculdade de Ciências Médicas de Minas Gerais, Belo Horizonte, Brazil
[3]Whipps Cross University Hospital, London, U.K.
[4]Royal London Hospital, London, U.K.
[5]Department of Dermatology, Hopitaux Universitaires de Strasbourg, Strasbourg, Alsace, France
[6]Department of Dermatology, University of KwaZulu-Natal College of Health Sciences, Durban, South Africa
[7]Haut- und Laserklinik, Konz, Germany
[8]Department of Ophthalmology and Vision Science, University of California Davis, Davis, CA, U.S.A.
[9]National Skin Centre, Singapore
[10]Apollo Hospitals Enterprise, Chennai, Tamil Nadu, India
[11]Department of Dermatology and UCD Charles Institute for Translational Dermatology, University College Dublin, Dublin, Ireland
[12]Department of Dermatology, Pennsylvania State University College of Medicine, Hershey, PA, U.S.A.
[13]Faculty of Dermatology, Universidad de Buenos Aires, School of Medicine, Buenos Aires, Argentina
[14]Department of Dermatology and Cutaneous Biology, Sidney Kimmel Medical College at Thomas Jefferson University, Philadelphia, PA, U.S.A.
[15]Department of Dermatology, Peking University First Hospital, Beijing, China
[16]Department of Dermatology, Leiden University Medical Centre, Leiden, the Netherlands
[17]Department of Medicine, University of Western Ontario, Windsor, ON, Canada

Linked Editorial: Drucker. *Br J Dermatol* 2017; **176**:283–284.
Linked Comment: Egeberg. *Br J Dermatol* 2017; **176**:300–301.

Treatment goal setting 2017

,,Treatment goals in rosacea should be based on discussion of severity and the psychosocial burden.,,

,,The majority of panellists agreed that they would treat an individual feature when it bothered the patient, regardless of severity.,,

The triad of rosacea care

- Education,
- Skin care,
- Treatment.
- BE Elewski et al 2011.

Principles of treatment – holistic approach

- Life style,
- Sun exposure,
- Diet,
- Skin care,

Principles of treatment-holistic approach

- Local treatment,
- General treatment,
- Laser treatment.

- Some of the most efficient drugs used are characterized by immune modulation properties.

Topical Azelaic Acid

- inhibit the expression of KLK-5 in cultured keratinocytes
- treatment with azelaic acid induce the decrease of expression of KLK-5 and cathelicidin mRNA,

Coda, A.B.; Hata, T.; Miller, J.; Audish, D.; Kotol, P.; Two, A.; Shafiq, F.; Yamasaki, K.; Harper, J.C.; del Rosso, J.Q.; et al. Cathelicidin, kallikrein 5, and serine protease activity is inhibited during treatment of rosacea with azelaic acid 15% gel. J. Am. Acad. Dermatol. 2013, 69, 570–577.

- anti-inflammatory properties,
- inhibiting the production of ROS and the UVB-induced upregulation of proinflammatory cytokines (IL-1, IL-6, and TNF-α).

Elewski, B.; Draelos, Z.; Dreno, B.; Jansen, T.; Layton, A.; Picardo, M. Rosacea–global diversity and optimized outcome: proposed international consensus from the Rosacea International Expert Group. J. Eur. Acad. Dermatol. Venereol. 2011, 25, 188–200.

Doxycycline….

- inhibits MMP-9 (production, activity),

Kim, H.S.; Luo, L.; Pflugfelder, S.C.; Li, D.Q. Doxycycline inhibits TGF-β1-induced MMP-9 via Smad and MAPK pathways in human corneal epithelial cells. Investig. Ophthalmol. Vis. Sci. 2005, 46, 840–848.

- inhibits other MMPs (conformational changes and functional abnormalities),

Golub, L.M.; Lee, H.M.; Ryan, M.E.; Giannobile, W.V.; Payne, J.; Sorsa, T. Tetracyclines inhibit connective tissue breakdown by multiple non-antimicrobial mechanisms. Adv. Dent. Res. 1998, 12, 12–26.

- indirectly inhibit the activation of KLK in vitro,

Di Nardo, A.; Holmes, A.D.; Muto, Y.; Huang, E.Y.; Preston, N.; Winkelman, W.J.; Gallo, R.L. Improved clinical outcome and biomarkers in adults with papulopustular rosacea treated with doxycycline modified-release capsules in a randomized trial. J. Am. Acad. Dermatol. 2016.

Doxycycline….

- inhibit the NO synthase activity (inhibit vasodilatation),
- anti-inflammatory effects.

D'Agostino, P.; Arcoleo, F.; Barbera, C.; di Bella, G.; La Rosa, M.; Misiano, G.; Milano, S.; Brai, M.; Cammarata, G.; Feo, S.; et al. Tetracycline inhibits the nitric oxide synthase activity induced by endotoxin in cultured murine macrophages. Eur. J. Pharmacol. 1998, 346, 283–290.

- sub-antimicrobial-dose decreased inflammatory lesion counts and erythema scores,

Del Rosso, J.Q.; Webster, G.F.; Jackson, M.; Rendon, M.; Rich, P.; Torok, H.; Bradshaw, M. Two randomized phase III clinical trials evaluating anti-inflammatory dose doxycycline (40-mg doxycycline, USP capsules) administered once daily for treatment of rosacea. J. Am. Acad. Dermatol. 2007, 56, 791–802.

- a sub-antimicrobial-dose decrease the release of inflammatory cytokines and downregulate the production of ROS.

Wise, R.D. Submicrobial doxycycline and rosacea. Compr. Ther. 2007, 33, 78–81.

Macrolides…

- immunomodulatory activities,
- reducing chemotaxis and pro inflammatory citokine production,
- decreasing adhesion molecule expression,
- decreasing ROS production.

,,Immune modulation concept,,

- **,,It must be pointed out that immune modulation is the suppression of inflammation and immune hyperactivation without causing immune depression (immunosuppression).,,**

M. Shinkai and B. K. Rubin, "Macrolides and airway inflam- mation in children," *Paediatric Respiratory Reviews*, vol. 6, no. 3, pp. 227–235, 2005.

- **,,Interest in the immunomodulatory effects of macrolides began in the 1960s with the observation that the 14-member antibiotic, troleandomycin, was an effective "steroid- sparing" agent when used to treat patients with severe asthma.,,**

S. L. Spector, F. H. Katz, and R. S. Farr, "Troleandomycin: effectiveness in steroid dependent asthma and bronchitis," *Journal of Allergy and Clinical Immunology*, vol. 54, no. 6, pp. 367–379, 1974.

Non antimicrobial ,,effects,,

- modify host functions apart from the antimicrobial potency.
- directly influence phagocyte and lymphocyte function, and chemotaxis.
- effects on the generation and release of various cytokines involved in the inflammatory process.

- T. Brinkmeier and P. J. Frosch, “Oral antibiotics with antiinflammatory/immunomodulatory effects in the treatment of various dermatoses,” *Hautarzt*, vol. 53, no. 7, pp. 456–465, 2002.

Rosacea = laser and light therapy

- Feldman SR, Huang WW, Huynh TT. Current drug therapies for rosacea: a chronic vascular and inflammatory skin disease. J Manag Care Pharm. 2014;20:623-629.
- Fowler J Jr, Jackson JM, Moore A, et al. Efficacy and safety of once-daily topical brimonidine tartrate gel 0.5% for the treatment of moderate to severe facial erythema of rosacea: results of two randomized, double-blind, vehicle-controlled pivotal studies. J Drugs Dermatol. 2013;12:650-656.
- Moore A, Kempers S, Murakawa G, et al. Long-term safety and efficacy of once-daily topical brimonidine tartrate gel 0.5% for the treatment of moderate to severe facial erythema of rosacea: results of a 1-year open-label study. J Drugs Dermatol. 2014;13:56-61.
- Generali JA, Cada DJ. Oxymetazoline (topical): rosacea. Hosp Pharm. 2013;48:558-559.
- Tanghetti E, Del Rosso JQ, Thiboutout D, et al. Consensus recommendations from the American Acne & Rosacea Society on the management of rosacea, part 4: a status report on physical modalities and devices. Cutis. 2014;93:71-76.

Laser treatment in rosacea

- the cause and pathogenesis of rosacea = unknown,
- FACT = strong vascular component.

- Plewig G, Jansen T. Rosacea. In: Freedberg IM, Eisen AZ, Wolff K, Austen KF, Goldsmith LA, Katz SI, et al, editors. Fitzpatrick's dermatology in general medicine. 5th ed. New York: McGraw- Hill; 1999. p. 785-94.

Laser treatment…

- The best = NO!
- The best for moment / patient / health status / ,,problem,, =

YES!

History….

- Vascular laser therapy for rosacea began in the early 1980s with the argon laser (488-514 nm).

- Dicken CH. Treatment of the red nose with the argon laser. Mayo Clin Proc 1986;61:893-5.
- Noe JM, Finley J, Rosen S, Arndt KA. Postrhinoplasty "red nose": differential diagnosis and treatment by laser. Plast Reconstr Surg 1981;67:661-4.
- Arndt KA. Argon laser therapy of small cutaneous vascular lesions. Arch Dermatol 1982;118:220-4.
- Barsky SH, Rosen S, Geer DE, Noe JM. The nature and evolution of port wine stains: a computer-assisted study. J Invest Dermatol 1980;74:154-7.

Laser treatment - effects

- ablation of vascular anomalies (destroy small vessels and reducing the symptoms),
- decreasing erythema and telangiectasia, and the flushing symptoms,
- reorganization and remodeling of dystrophic dermal connective tissue,
- strengthening of the epidermal barrier.
- interruption of the release of inflammatory mediators.

- Pelle MT, Crawford GH, James WD. Rosacea: II. Therapy. *J Am Acad Dermatol*. 2004;51:499–512.
- Adamic M, Troilius A, Adatto M, et al. Vascular lasers and IPLS: guidelines for care from the European Society for Laser Dermatology (ESLD). *J Cosmet Laser Ther*. 2007;9:113–124
- Lonne-Rahm S, Nordlind K, Edström DW, et al. Laser treatment of rosacea. *Arch Dermatol*. 2004;140:1345–1349.
- Gallo R, Drago F, Paolino S, Parodi A. Rosacea treatments: what's new and what's on the horizon? *Am J Clin Dermatol*. 2010;11:299–303

Type-1 rosacea = erythematotelangiectatic type ETR

- **Pulsed dye laser (PDL, 585-595 nm),**
- Potassium titanyl phosphate (KTP, 532 nm),
- **Intense pulsed light (IPL, 500-1200 nm),**
- Dual-wavelength lasers,
- **Long-pulsed neodymium:yttrium-aluminum-garnet laser (Nd:YAG, 1064 nm)**

Papulo-pustular rosacea

- long-pulsed 1064-nm neodymium: yttrium-aluminum-garnet laser (LPND),

- Lee, J.H.; Kim, M.; Bae, J.M.; Cho, B.K.; Park, H.J. Efficacy of the long-pulsed 1064-nm neodymium:yttrium-aluminum-garnet laser (LPND) (rejuvenation mode) in the treatment of papulopustular rosacea (PPR): A pilot study of clinical outcomes and patient satisfaction in 30 cases. *J. Am. Acad. Dermatol.* **2015**, *73*, 333–336.

- review of laser and rosacea

- Lonne-Rahm, S.; Nordlind, K.; Edstrom, D.W.; Ros, A.M.; Berg, M. Laser treatment of rosacea: A pathoetiological study. *Arch. Dermatol.* **2004**, *140*, 1345–1349.

Nd:YAG and Rosacea

- destruction of the follicular unit by Nd:YAG,

Crawford GH, Pelle MT, James WD. Rosacea: I. Etiology, pathogenesis, and subtype classification. *J Am Acad Dermatol*. 2004;51:327–341.

Tan ST, Bialostocki A, Armstrong JR. Pulsed dye laser therapy for rosacea. *Br J Plast Surg*. 2004;57:303 310

- Nd:YAG penetrate deeply / treatment of deeper vessels.
- more safely for darker skin,
- the risk for postinflammatory hyper pigmentation is very low.

Railan D, Parlette EC, Uebelhoer NS, Rohrer TE. Laser treatment of vascular lesions. *Clin Dermatol*. 2006;24: 8–15.

PDL / Inflammatory lesions / Antibiotic

- reduction in inflammatory lesions.

Clark SM, Lanigan SW, Marks R. Laser treatment of erythema and telangiectasia associated with rosacea. Lasers Med Sci 2002;17:26-33.

- a reduction in the dose of concurrent oral antibiotic therapy has been possible after PDL treatment.

Lowe NJ, Behr KL, Fitzpatrick R, Goldman M, Ruiz-Esparza J. Flash lamp pumped dye laser for rosacea-associated telangiectasia and erythema. J Dermatol Surg Oncol 1991;17: 522-5.

- NOT cure / YES control!
- NOT favorable effects ,,overnight,,
- NO best treatment!

My way…

- NOT laser treatment at the first visit,
- Complex and holistic evaluation,
- Change the life style of patient = diet, sun exposure, skin care,
- Local and general treatment,
- Indication and contraindication for laser,
- Follow up.

Practical approach….

- NOT laser treatment at the first visit,
- Complex and holistic evaluation,
- Change the life style of patient = diet, sun exposure, skin care,

- Local and general treatment,
- Indication and contraindication for laser,
- Follow up.

- Immunity = important role in pathogeny,
- Holistic approach (education, skin care, local and systemic treatment, vascular laser and nanotechnology),
- **Immunomodulation (local and general treatment, laser, nanotechnology) =**

FUTURE!!!


TEAM
WORK